

Treatment Considerations for Implant Restoration of the Edentulous Patient

Dr Brenda Baker BDS (Syd) Hons. MSc Conservative Dentistry (London)
Southern Cross Dental

Dental implants replace missing teeth and maintain alveolar bone. After a tooth is removed, there is a reduction in the trabeculation of the bone. Once an implant is placed and in function, this process is reversed and there is an increase in the bone trabeculation and density. The overall volume of the bone is maintained. Patients with natural teeth can perceive a difference of 20 microns between the teeth. Patients with implants can perceive a 50 micron difference with rigid implant bridges as compared with 100 microns in a complete denture wearer (Lundqvist S, Haraldson T. 1984).

Researchers at McGill University checked blood levels of patients who had full dentures and 30 maxillary dentures and mandibular implant prostheses 6 months after treatment. After this short time period, implant patients were shown to have a higher B12 haemoglobin (related to iron increase) and albumin levels which is associated with nutrition. The patients were found to have greater body fat in their shoulders and arms with decreased body fat around the waist (Doundoulakis, JH. et al., 2003).

The use of implants as support for prostheses compared with the use of removable soft tissue-borne prostheses has been shown to have many advantages:

- Bone is maintained
 - Occlusal vertical dimension is restored and maintained
 - Facial aesthetics are maintained via muscle tone
 - Facial profile may be enhanced for a longer period with implants
 - Aesthetics are improved as teeth are positioned for appearance versus decreasing denture movement
 - Phonetics is improved
 - Occlusion is enhanced
 - Oral proprioception and occlusal awareness are improved or regained
 - Masticatory efficiency is enhanced
 - Masticatory muscle function and facial expression are improved
 - The size of the prosthesis is reduced
 - Enhanced stability and retention is provided
 - The survival time of the prosthesis is lengthened
 - Adjacent teeth remain unaltered
 - Psychological health is improved.
- The prosthetic teeth associated with

the mandibular denture are placed to achieve stability rather than being placed in the position of where the natural teeth reside. When implants are employed, the teeth can be placed to improve aesthetics and phonetics instead of in a neutral zone as is the standard technique when making conventional dentures. As a mandibular denture can move as much as 10 mm or more in function, proper occlusal contacts happen more by chance and not by intent (Sheppard IM, 1963, Smith D. 1963).

Many prosthetic alternatives are available to rehabilitate edentulous mandibles: conventional complete dentures, implant-supported fixed restorations, implant-retained and tissue-supported overdentures, implant-retained and implant-supported overdentures and fixed prostheses with processed acrylic teeth commonly referred to as "hybrid prostheses."

All these treatments have advantages and disadvantages associated with them. Financial considerations, patient motivation, treatment complexity, aesthetic and functional expectations all contribute to planning the most suitable restorative option (Morin C. et al., 1998).

Dissatisfaction is experienced by full denture wearers with function, aesthetics and phonetics (Awad M. et al., 1998). Thus the provision of implants may allow greater stability, retention, comfort and reduced bone resorption (Awad M. et al., 2002).

The advent of new implant surfaces and prosthetic connections has heralded a new era in implant dentistry. Implants with roughened surfaces have a higher survival rate than machined-surface implants (Lambert FE. et al. 2009). Platform switching and inward shift of the connection microgap has reduced crestal bone remodelling (Trammell K. et al., 2009). The peri-implant bone remodelling was once recognized as being up to 2 mm during the first year of function and then a maximum of 0.2 mm/annum thereafter and this may now be under scrutiny.

Age is no longer seen as an absolute contraindication for provision of implants. A study (Engfors I. et al, 2004) reviewed 133 edentulous patients who were 80 or more years of age and who were consecutively treated with fixed implant-retained prostheses. Seven hundred and sixty-one Branemark type

implants were placed in 139 edentulous jaws. The five year survival rate for the group for both jaws was 93%.

Careful assessment, proper diagnosis and treatment planning are critical to achieve a successful outcome (Handelsman M. 2006). "Multiple surgical and restorative factors play a role in the treatment planning of implant restorations for the edentulous patient (Ali B, Bhavani V. 2014)".

Critical restorative factors include a complete examination and evaluation of:

- Hard and soft tissues
- Need for lip support
- Location of occlusal plane
- Available restorative space
- Number, position and angulation of implants (Stamford CM., 2005).

Generation of CAD designs of full-arch implant-supported bridges are based on diagnostic wax-ups which allows for proper design for strength and retention (Thalji G. et al., 2014). "The use of CAD/CAM technologies for fabricating implant superstructures has proven advantageous in the quality of materials, accuracy of the milled superstructures and passive fit" (Almasri R. et al., 2011, Örtorp A. et al., 2011).

Criteria to be used as design principles critical to the fabrication of implant framework may include sufficient access for oral hygiene, mechanical strength and the least amount of visible metal on the buccal and occlusal surfaces (Lin WS., 2014). However, the bulk of the frameworks are smaller and cantilevers should be avoided. The precision of the framework fit is essential for optimal screw mechanics. Several longitudinal clinical studies have shown that poorly-fitting frameworks may be one of the main causes of screw loosening or fracture, abutment fractures and even implant fractures (Jemt T. et al., 1994).

Several materials have been used in the manufacture of implant frameworks which include:

- Noble metals
- Base-metal alloys
- Titanium and its alloys

The choice of metal is largely dependent on the casting accuracy, hardness, modulus of elasticity and handling properties. Metal-ceramic fixed units require more implants to support the restoration for biomechanical, technical and ease of maintenance issues.

One of the main determinants of

the type of implant restoration for the edentulous patient is the restorative space. Implant-retained fixed dental prostheses and bar overdentures require at least 13-14 mm between the crest of the ridge and the occlusal plane. Overdentures retained by Locator (Locator®; Zest Anchors) attachments require at least 8.5 mm (Sadowsky SJ., 2007).

Other factors which determine prosthetic success are implant location and angulation which depend on the tooth position. The determination of tooth position is an essential part of the diagnostic process. One of the best ways available to the clinician to aid in the pre-treatment assessment is the patient's existing denture. This can assist the dentist to identify the preferences of the patient and assess expectations.

If the patient presents with a well-fitting and aesthetically pleasing existing complete denture prosthesis, it can often be duplicated and used as a radiographic and surgical guide for implant placement. If the prosthesis is not acceptable, a diagnostic wax-up and new interim prosthesis should be made which can be evaluated for aesthetics and phonetics prior to surgery. The implant surgery must be planned in conjunction with a complete restorative work-up so that the prosthetic outcome is as optimal as possible.

HISTORY

A female patient aged 62 presented to the practice. The main concerns were that she had been wearing the same full upper denture for 40 years. There were still 2 third molars in the upper jaw that were worn down to the gum line. Nine teeth were present in the lower jaw, which were deemed unsalvageable. The patient expressed a desire to have the lower teeth removed and new full upper and full lower dentures constructed. The patient's wish was not to have to go to the dentist again.

The dentist discussed expectations of treatment outcomes with the patient and what the patient's long-term goal was for her teeth. There were clear objectives to have better masticatory function, aesthetic requirements, improved speech and an improved sense of well-being. The patient reported that three anterior teeth exfoliated naturally in the last 3 weeks and chewing was not problematic but the loss of the teeth had resulted in a lisp. The existing full upper denture had not been a problem over the years. Breakages had occurred with the denture which was repaired by gluing the denture.

The presenting condition is viewed in Fig. 1a, b, c and d.

EXAMINATION

The periodontium was examined and the periodontal measurements revealed 3-4 mm generalised probing depths. The lower anterior teeth showed grade 2 mobility. The diagnosis was severe adult periodontitis with a very poor prognosis.

The soft tissues and lymph nodes were examined and checked and found to be unremarkable, indicative of a clear oral cancer screening check.

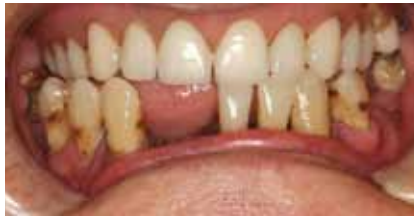

Fig. 1a Frontal view

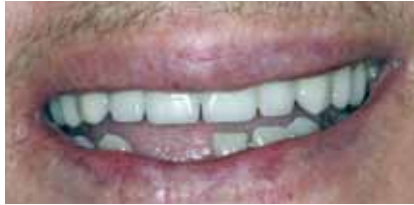

Fig. 1b Frontal view-smile

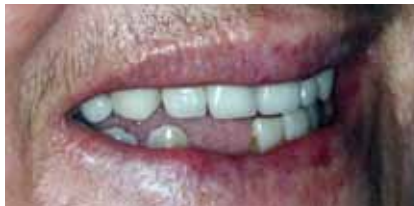

Fig. 1c Right lateral

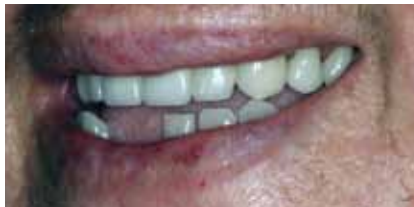

Fig. 1d Left lateral

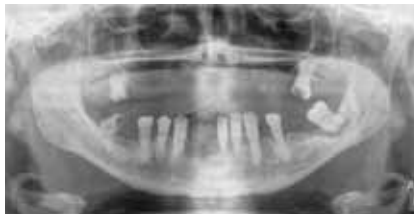

Fig. 2

The maxillary arch was examined and there was good bone height. Dimensionally the jaw was narrow and the patient was advised to replace the upper denture and slightly increase the vertical dimension of occlusion so that more tooth structure would be evident aesthetically.

RADIOGRAPHIC FINDINGS

The initial panoramic radiographic revealed irreversible destructive periodontitis. A significant periapical lesion was noted on the lower left mandibular molar (Fig. 2).

TREATMENT OPTIONS

The following treatment plan options were presented:

- 1) Full Upper Denture
- 2) Fixed implant-supported overdenture
- 3) Full Upper Denture with 3 or 4 implants removable

LOWER OPTIONS

- 1) Full Lower Denture
- 2) Full Lower Denture with 2 or 3 implants to support the denture as a removable
- 3) Fixed implant-supported overdenture

CLINICAL PROCEDURES

VISIT 1 (IMPLANT PLACEMENT AND PROSTHETIC STABILISATION - FIG. 3a-3d)

LA Used: Articaine 4% 1:100000 Adrenalin 10.8 mls inferior dental block Quadrant 3 Quadrant 4

Buccal flap raised Performed osteotomy to insert implant

35: MIS 3.75 x 8mm Seven internal hex LOT:W02196421 Torque 50Ncm

45: MIS 3.75 x 8mm Seven internal hex LOT:W13000918 Torque 50Ncm

Coverscrew placed

Sutured using Chromic Gut 5/0

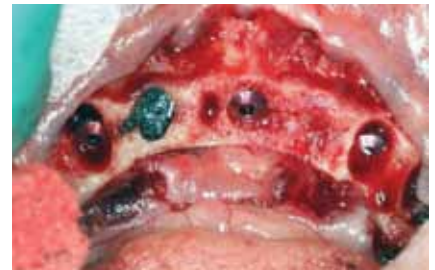

Fig. 3a Implant placement

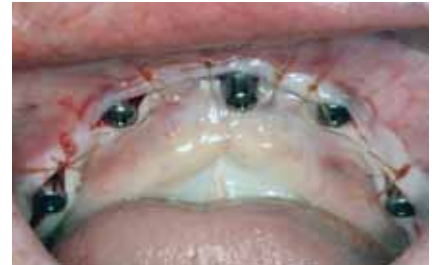

Fig. 3b Occlusal view of edentulous mandible with healing abutments in place.

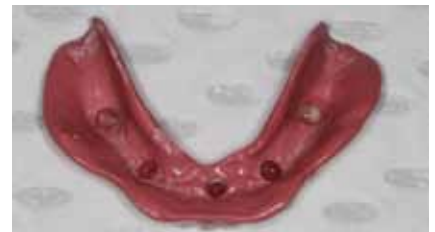

Fig. 3c The existing mandibular denture was relieved, relined and repolished.

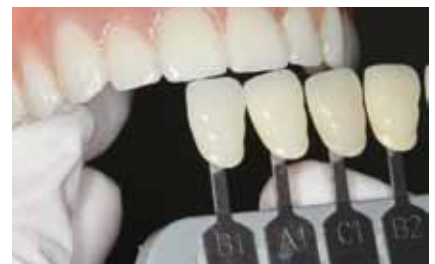

Fig. 3d Shade selection with existing denture

VISIT 2 (IMPRESSIONS FOR PROVISIONALISATION - FIG. 4a-4d)

Removed healing abutments and placed MIS pick up impression copings into 45, 43, 31, 33, 35. Lower impression using Affinis® (COLTENE) heavy and light body PVS.

Replaced healing caps.

Took upper alginate for special tray and bite block for new Full Upper Denture.

A combination approach of both screw and cement-retained restorations both in the intermediate prosthesis and

the final porcelain-fused-to-metal final restorations was employed.

Fixed provisionalisation was deemed necessary to ascertain functional, aesthetic and phonetic performance.

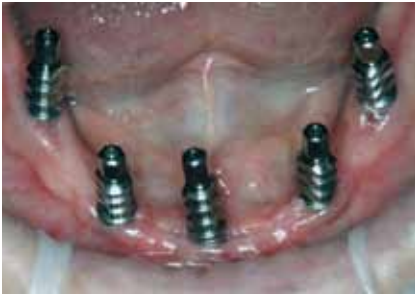

Fig. 4a Pick-up impression coping in place

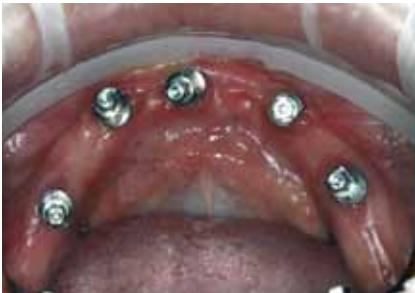

Fig. 4b Occlusal view of impression copings

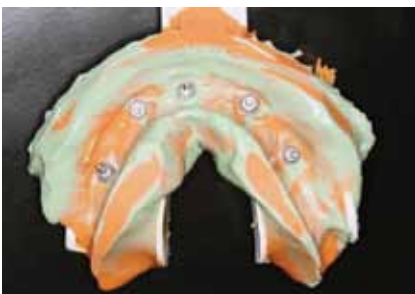

Fig. 4c Open-tray impression technique for the fabrication of the restorations.

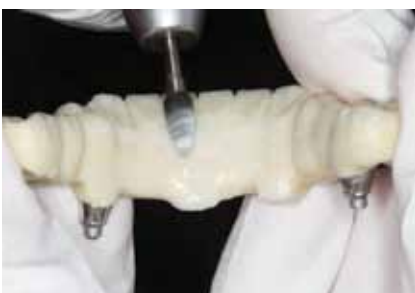

Fig. 4d Laboratory made provisionals

VISIT 3 FABRICATION OF ABUTMENTS (FIG. 5)

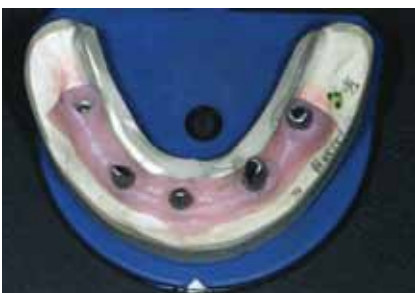

Fig. 5

VISIT 4 TRY-IN OF ABUTMENTS AND VERIFICATION INDEX (FIG. 6a-6c)

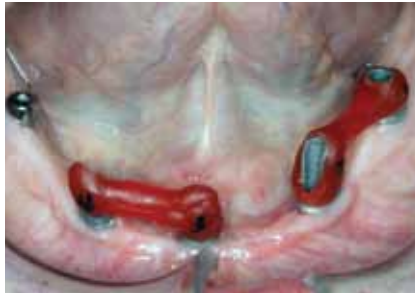


Fig. 6a

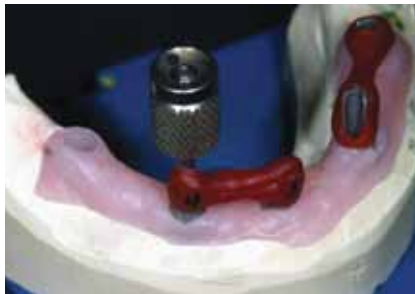


Fig. 6b

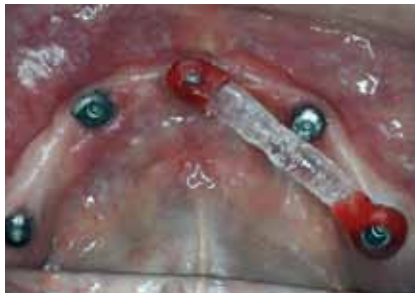

Fig. 6c

VISIT 5 TRY-IN AND FINAL ISSUE (FIG. 7a-7c, 8a-8b)

The implant bridge was inserted and checked and the patient and dentist were happy with shape, shade and fit. The prosthesis was issued on the same day and screwed in on the right hand side to 32Ncm.

The bridge was cemented onto the abutments using Freegenol™ NE (GC America).

The access hole was sealed with silicone tape, ceramic etch, metal primer, Calibra™ silane, Clearfil™ SE bond, bellglass opaque, A1 flowable and P-A1 G-ænial composite (GC Europe).

Temporary cement was used on the

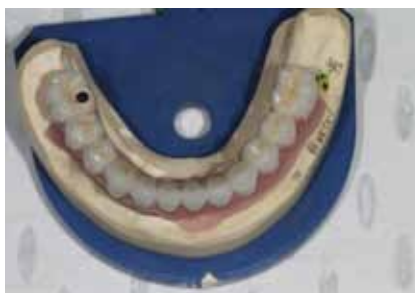

Fig. 7a

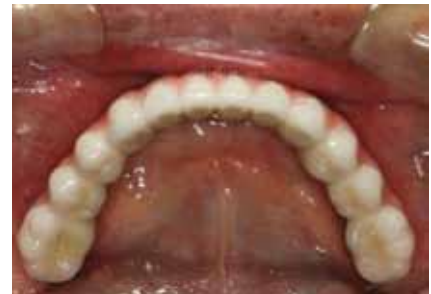

Fig. 7b

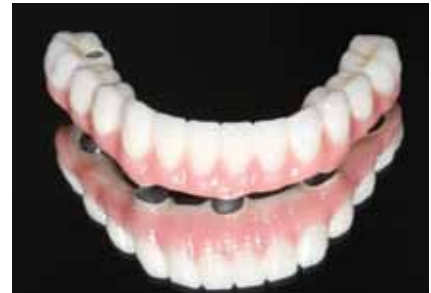

Fig. 7c

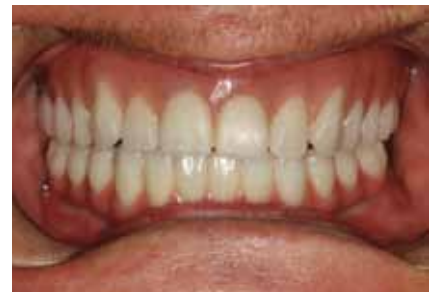

Fig. 8a

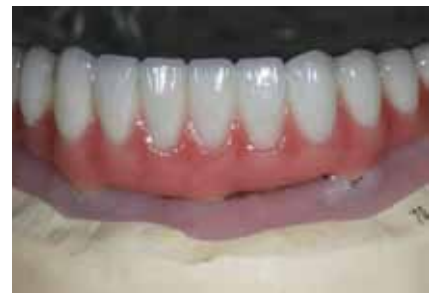

Fig. 8b

abutments to achieve a passive fit and a screw-retained restoration was included in the prosthesis so that it did not fall out.

The occlusion was checked and adjusted and then polished.

Southern Cross Dental would like to acknowledge and thank Dr Lincoln Harris, Bagara, Queensland for the presentation of this clinical case. ■

Contact gapmagazines@optusnet.com.au for a complete list of references.

By Dr Brenda Baker

BDS Hons. (Syd) MSc.
Conservative Dentistry
(London)
Senior Clinical & Technical
Support Consultant Southern
Cross Dental

