

SCD

# Case Study

Resorption is associated with either a physiologic or a pathologic process resulting in a loss of dentine, cementum and/or bone ([www.aae.org/glossary](http://www.aae.org/glossary)).

The aetiology for resorption starts from injuries to the tooth, including thermal, mechanical and chemical (Nilsson E., 2013) factors. Pathologic resorption can also occur from orthodontic tooth movement or from chronic infections of the pulp or periodontal tissues (Ne RF. et al., 1999).

Root resorption may be classified based on its location in relation to the root surface: external root resorption (ERR) and internal root resorption (IRR). External resorption is resorption that starts in the periodontium and initially affects the external surfaces of a tooth. It can be further classified as surface, inflammatory, replacement, or by location as cervical, lateral, or apical. It may or may not invade the dental pulp space ([www.aae.org/glossary](http://www.aae.org/glossary)).

Internal resorption is an inflammatory process which starts within the pulp space with loss of dentine and possible invasion of cementum ([www.aae.org/glossary](http://www.aae.org/glossary)). Internal resorption is rare compared with external resorption.

## Pathogenesis

Osteoclasts are multinucleated giant cells which cause bone resorption. They are formed by fusion of mononuclear precursor cells that reach the resorption site via the blood stream. Their differentiation is controlled by factors made by the bone marrow stromal cells or found on the mature osteoblast. Two such factors are RANK (receptor activator of nuclear factor kappa B) ligand (RANKL) and osteoprotegerin (OPG). Both RANKL and OPG play an important role in osteoclastinogenesis (Patel S. et al., 2010).

The pathology of internal root resorption is caused by transformation of normal pulp tissue into granulomatous tissues with giant cells, which resorb dentine. This, in turn, resorbs the dentinal walls, advancing from the centre to the periphery.

There are two types of internal resorption: internal inflammatory resorption and internal replacement resorption.

**1. Inflammatory resorption** - the resorptive process occurs if the intraradicular dentine progresses without adjunctive deposition of hard tissues adjacent to the resorptive sites. The phenomenon is associated with the presence of granulation tissues in the resorbed area and is identifiable with routine radiographs as a radio clear zone centered on the root canal.

**2. Replacement resorption** - the resorptive activity causes defects in the dentine adjacent to the root canal, with concomitant deposition of bone-like tissue in some regions of the defect. It results in an irregular enlargement of the pulp space with partially or fully obliterated area of the pulp chamber.

Trauma and pulpal inflammation/infection are two of the main factors in the initiation of internal resorption (Nilsson E., 2013). A study done on patients diagnosed with IRR showed that 43% of the patients had trauma as a common cause, followed by carious lesions at 25%. (Caliskan MK, Turkun M., 1997).

IRR is typically detected clinically via routine radiographs. It is apparent in all areas of the root canal, particularly cervically. In order to obtain a differential diagnosis between internal resorption and external resorption, the clinician is advised to see whether or not there is a defined outline of the pulp chamber. If the pulp chamber outline is within the lesion itself, it is likely internal resorption. If the pulp chamber outline is seen within a radiolucent halo, then it is probably external resorption. CBCT has allowed more precise and complete diagnosis of IRR (and external root resorption) and is highly advised in early presentations of potential resorption (Nilsson E., 2013).

IRR is usually asymptomatic, but pain or discomfort may be the chief complaint if the granulation tissue has been exposed to oral fluids. The granulation tissue can clinically manifest itself as a “pink spot” where the crown dentine destruction is severe. (<http://www.dentistryiq.com/articles/2014/09/internal-resorption-a-brief-review-and-case-report.html>). The pink shade is related to the highly vascularised connective tissue adjacent to the resorbing cells and when the pulp becomes necrotic, it turns grey/dark grey. (Nilsson E., 2013).

Teeth with IRR test normally to pulpal and periapical tests until the lesion grows significantly in size, which then results in perforation (Walton & Torabinejad., 1996). Once necrosis of the pulpal tissue takes place, then the typical signs/symptoms of an abscess occur. Vital pulp tissue is required for IRR to take place; therefore, when there is complete pulpal necrosis, the growth of the resorption ceases because the resorbing cells are cut off from the blood supply and nutriment (Maria R. et al., 2014).

Once diagnosed, treatment considerations and prognosis must be completed. The prognosis for the long-term form and function of the tooth depends on the size of the lesion. The American Association of Endodontics ([www.aae.org/glossary](http://www.aae.org/glossary)) offers a general guide: ([www.aae.org/treatmentoptions](http://www.aae.org/treatmentoptions)).

PROGNOSIS	Favourable	Uncertain	Poor
	Small/medium defect	Large defect does not perforate the root	Large defect does perforate the root
	Small lesion in the apical or mid-root area	X	X

## Case Study

A healthy 65 year-old male presented to the surgery with the chief complaint of a loose front tooth which was uncomfortable upon chewing and pressure. A radiograph revealed significant bone loss around tooth 22 in addition to the focalised loss of internal tooth structure in the mid-third of the root (Fig. 1). The root was almost perforated. Clinical examination revealed a lack of recession with a Class III mobility. No drainage point or fistula were noted.

A diagnosis of internal resorption was given due to the focal point of radiolucency within the pulp chamber area. The ultimate fate of the tooth did not change. Due to the extent of the defect and the advanced bone loss, it was recommended that that tooth be removed and other restorative options be assessed.

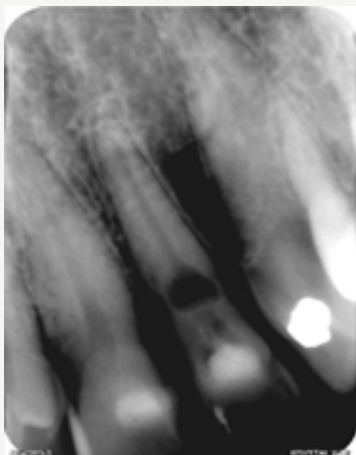


FIG. 1

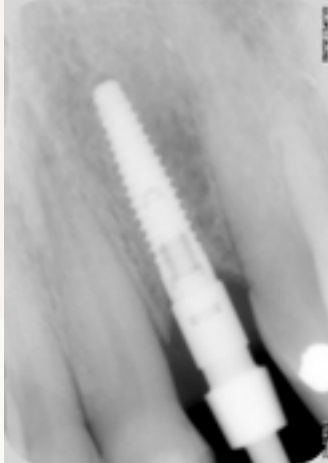Two days later, the patient called the practice to advise that the tooth crown had completely severed. An immediate flexible partial denture was fabricated for aesthetics and surgical removal of the tooth was planned with the oral surgeon.

### Implant placement:

Position 22 – Nobel Biocare Replace Select Narrow platform. Ref 36105 Implant placement in the position of tooth 22 was carried out under local anaesthetic on 29th May 2014. Bone quality was good and the implant was seated to 35Ncm. The implant was placed and a screw-retained restoration was planned. The implant was submerged during the healing phase and the removable partial denture was adjusted. An appointment was scheduled for 3 months later to expose the implant and the periodontist placed a 5mm healing abutment. Possible minor soft tissue augmentation was to be evaluated at that time.

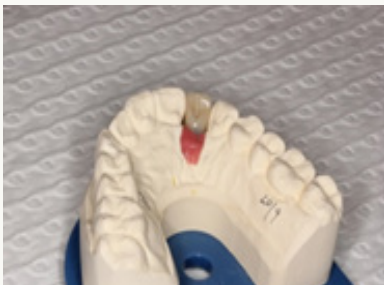**3 months later:**

The periodontist reported that the implant had integrated. An impression coping was employed using an open-tray impression technique (Fig. 2).

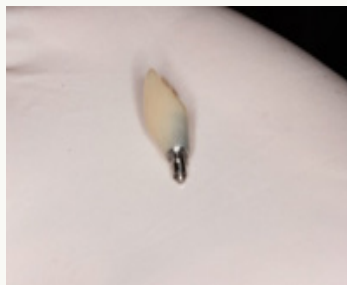

**FIG. 3**

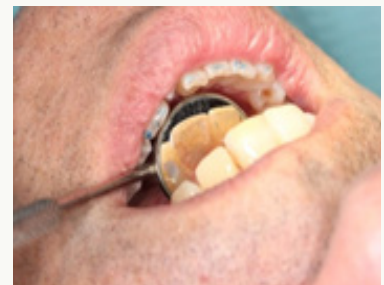In order to achieve excellent soft tissue contours, a provisional screw-retained temporary crown on a titanium base with a hybrid-ceramic was fabricated and left in situ for 2 months. (Fig. 3a, 3b and 3c).



**FIG. 3a**

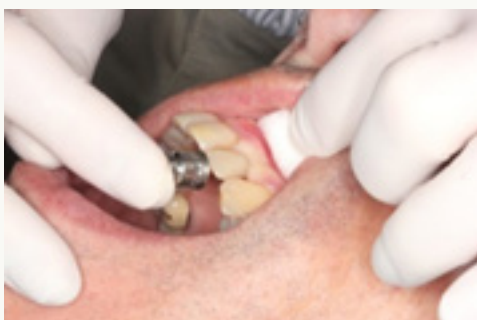

**FIG. 3b**



**FIG. 3c**

After two months, a screw-retained porcelain-fused-to-metal restoration was issued and the crown torqued to 32Ncm (Fig. 4).



**FIG. 4**

## References

American Association of Endodontics, "Glossary of endodontic terms," 2014. [www.aae.org/glossary](http://www.aae.org/glossary)

American Association of Endodontics website. [www.aae.org/treatmentoptions](http://www.aae.org/treatmentoptions).  
Internal Resorption.

Caliskan MK, Turkun M. Prognosis of permanent teeth with internal resorption: A clinical review. *Dental Traumatology*. 1997;13(2):75-81.

Nilsson, Elisabeth, Eric Bonte, François Bayet, and Jean-Jacques Lasfargues. "Management of Internal Root Resorption on Permanent Teeth." *International journal of dentistry* 2013 (2013).

Maria R, Mantri V, Koolwal S. Internal resorption: A review and case report. [medind.nic.in/aaa/t10/i1/aaat10i1p98.pdf](http://medind.nic.in/aaa/t10/i1/aaat10i1p98.pdf)

Ne, Rita F., David E. Witherspoon, and James L. Gutmann. "Tooth resorption." *QUINTESSENCE INTERNATIONAL-ENGLISH EDITION*- 30 (1999): 9-26.

Patel, Shanon, Domenico Ricucci, Conor Durak, and Franklin Tay. "Internal root resorption: a review." *Journal of endodontics* 36, no. 7 (2010): 1107-1121.

*Principals and Practice of Endodontics*. 2nd Edition. Walton & Torabinejad. WB Saunders Company. 1996. 36.

Simmons SL. <http://www.dentistryiq.com/articles/2014/09/internal-resorption-a-brief-review-and-case-report.html>